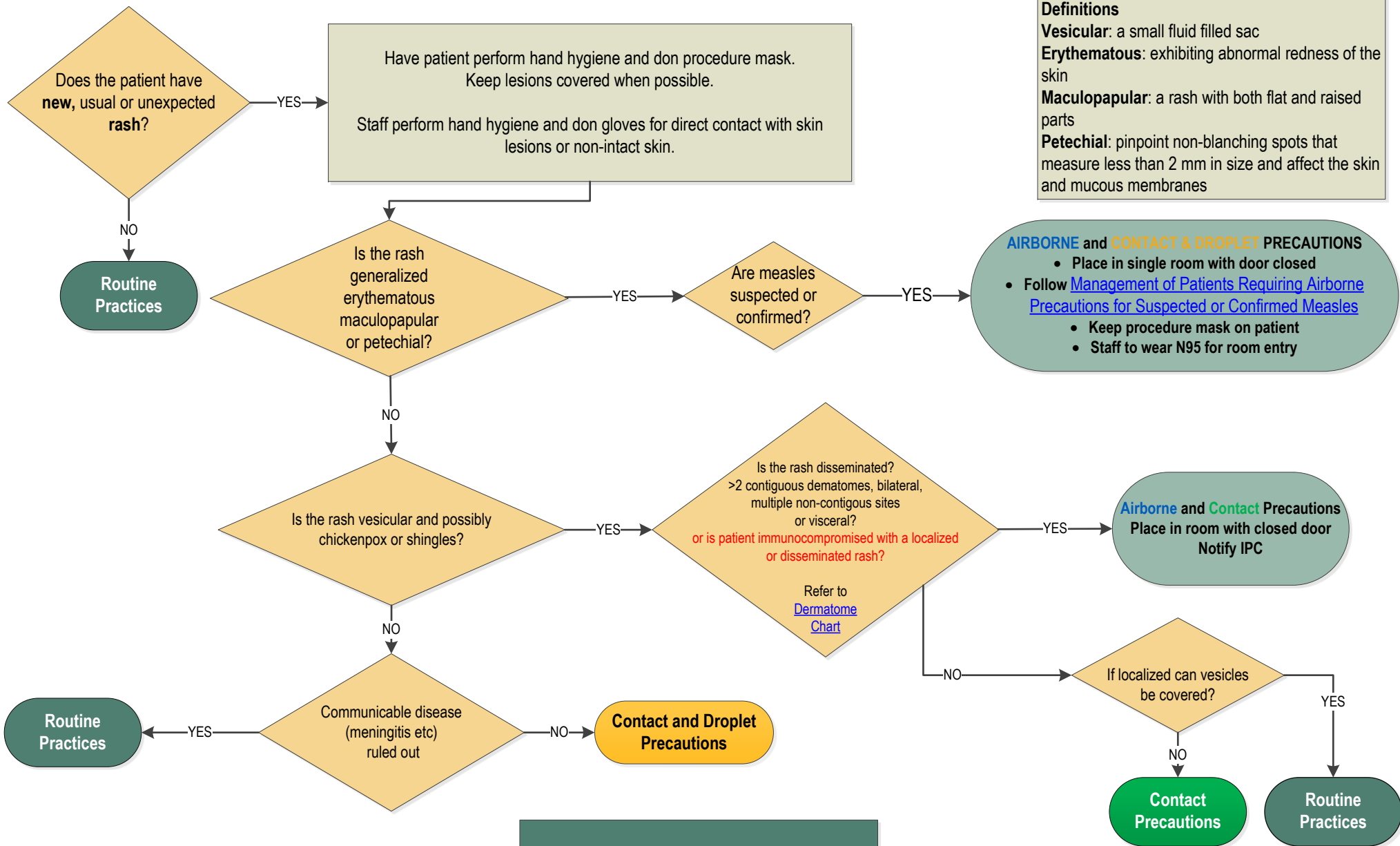


Rash: Assessing the Need for Additional Precautions (Isolation)



Definitions
Vesicular: a small fluid filled sac
Erythematous: exhibiting abnormal redness of the skin
Maculopapular: a rash with both flat and raised parts
Petechial: pinpoint non-blanching spots that measure less than 2 mm in size and affect the skin and mucous membranes

AIRBORNE and CONTACT & DROPLET PRECAUTIONS

- Place in single room with door closed
- Follow [Management of Patients Requiring Airborne Precautions for Suspected or Confirmed Measles](#)
- Keep procedure mask on patient
- Staff to wear N95 for room entry

Airborne and Contact Precautions
 Place in room with closed door
 Notify IPC

Refer to the [IPC Diseases and Conditions Table Recommendations for Management of Patients Acute Care](#)

