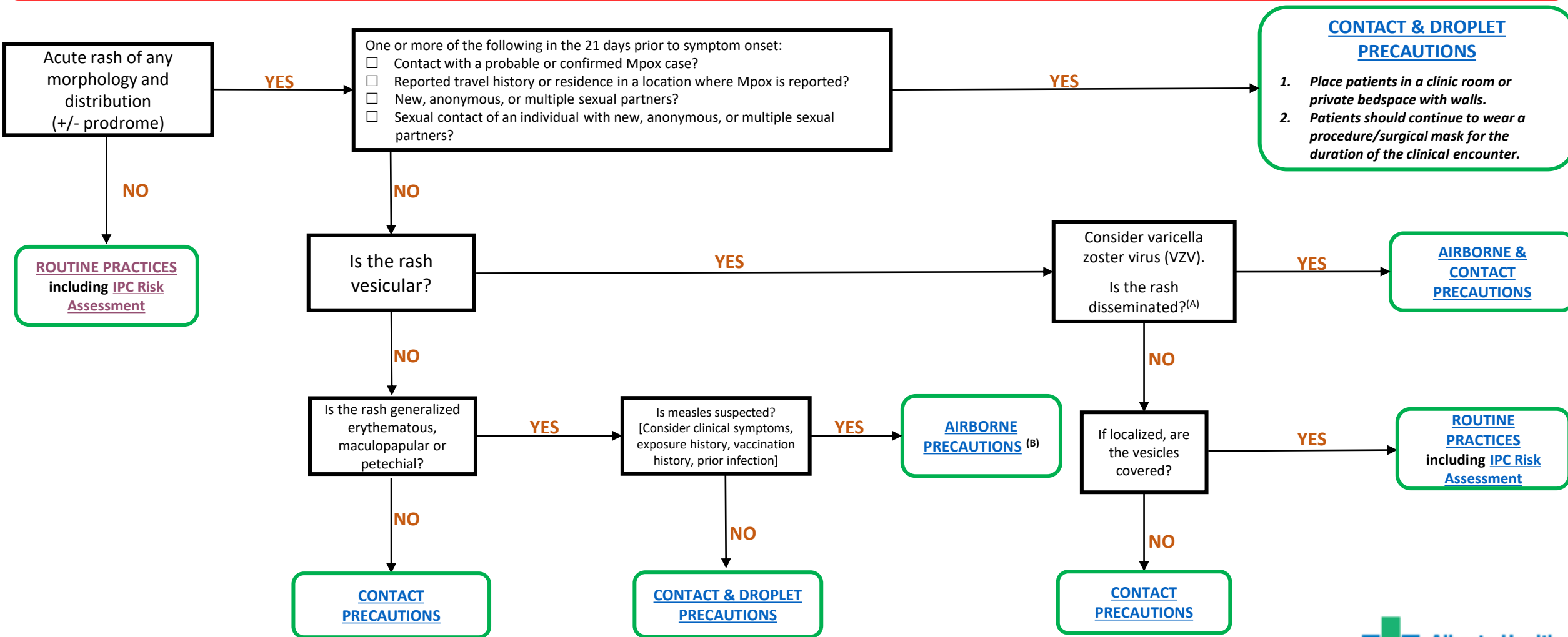


AHS IPC Algorithm for Suspect/Probable Mpox in Healthcare Settings

All patients who are considered suspect or probable cases of Mpox should wear a surgical mask throughout the entire clinical encounter.
Place masked patient in a clinic room/private bedspace immediately upon arrival (i.e. should not wait in waiting room).

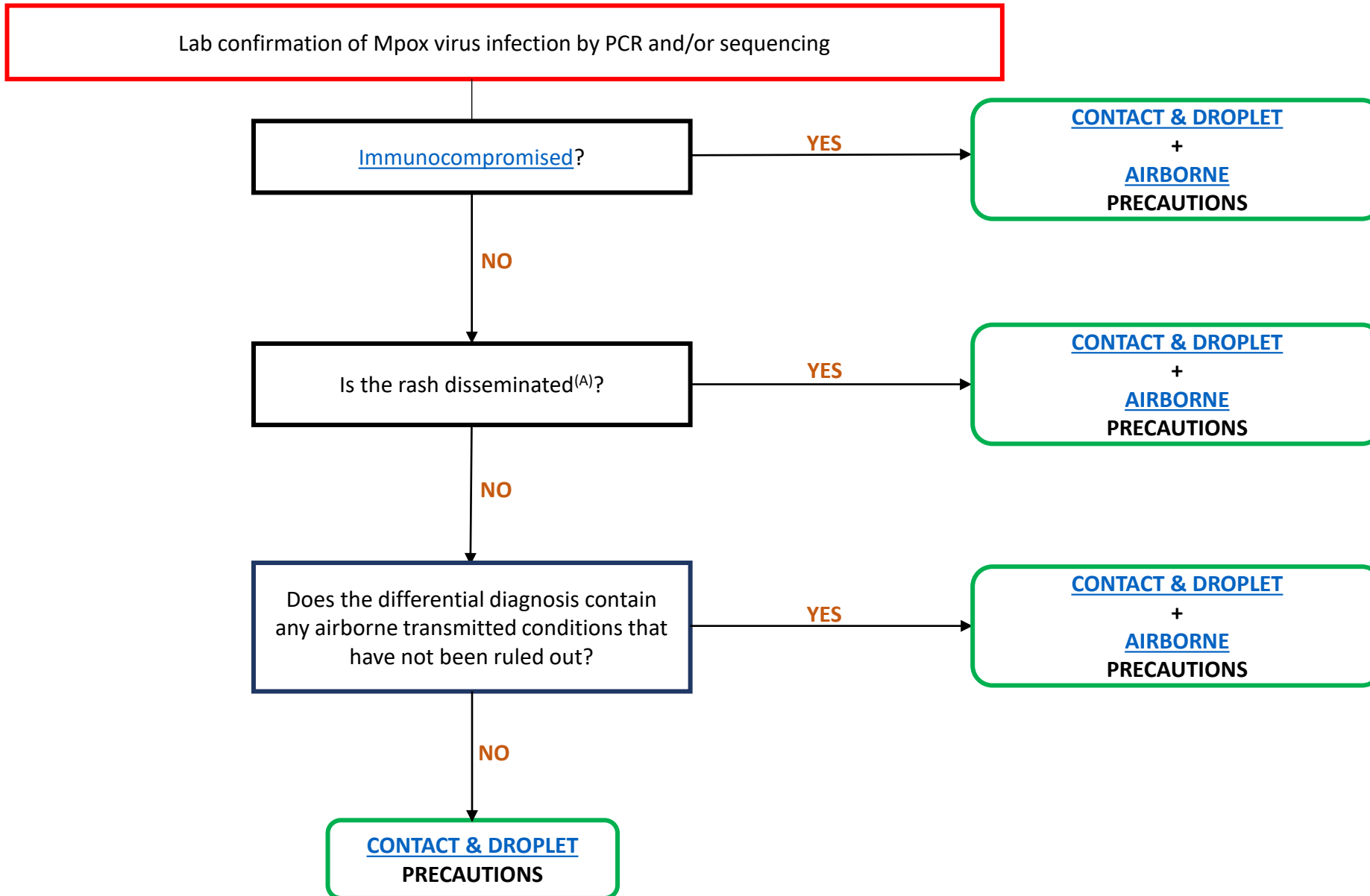
All healthcare workers who collect specimens to test for Mpox should use [Contact and Droplet Precautions](#).



(A) Disseminated VZV includes any of the following: Vesicular lesions that involve multiple areas (3 or more dermatomes), non-contiguous lesions, bilateral lesions, and/or visceral complications.

(B) The presence of a “wet rash” in suspected/confirmed measles may warrant the use of Contact Precautions in addition to Airborne Precautions.

AHS IPC Algorithm for Confirmed Mpox in Healthcare Settings



(A) **Disseminated Mpox:** usually involves a centrifugal rash with generalized lesions on the face, trunk, and extremities.
Non-disseminated Mpox: the typical rash distribution from the current outbreak is more limited to perioral, genital, and/or perianal lesions.