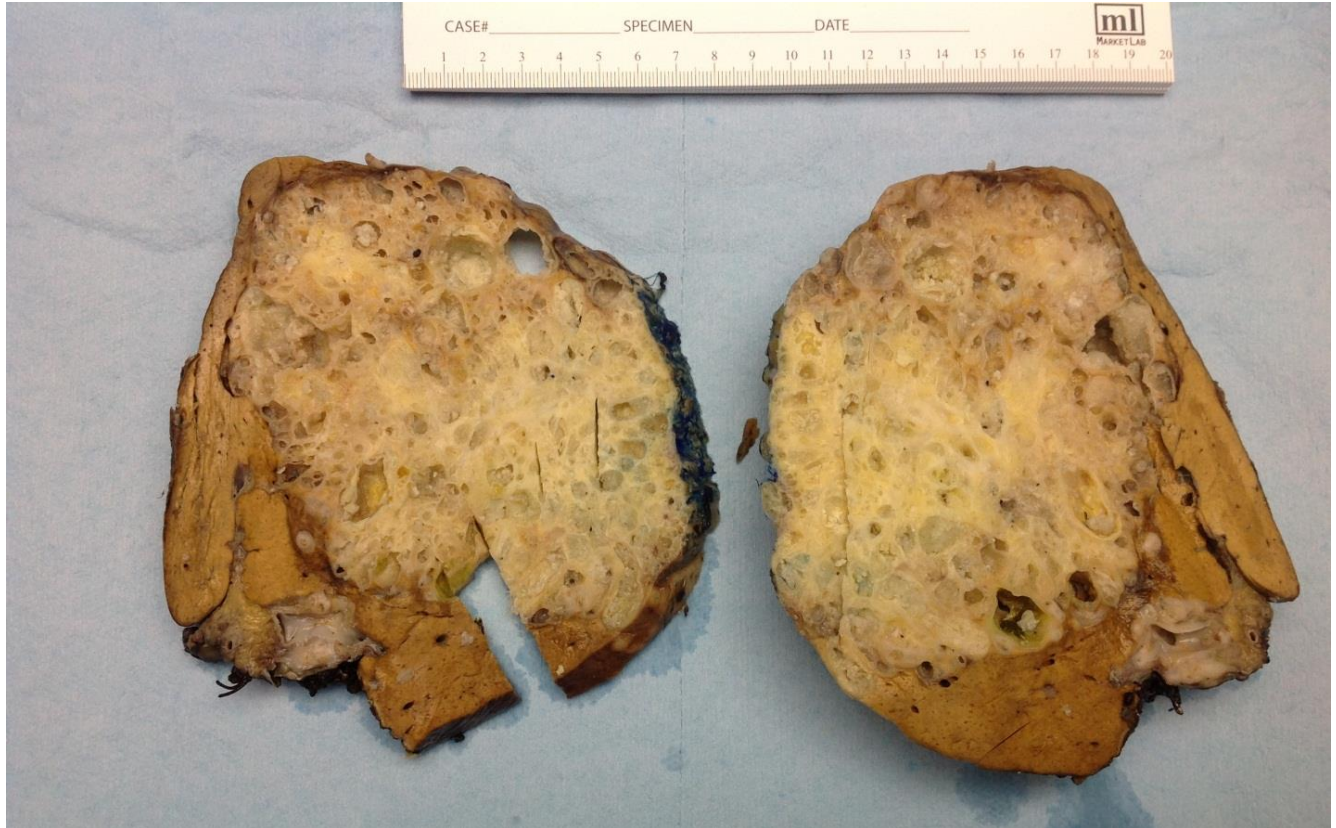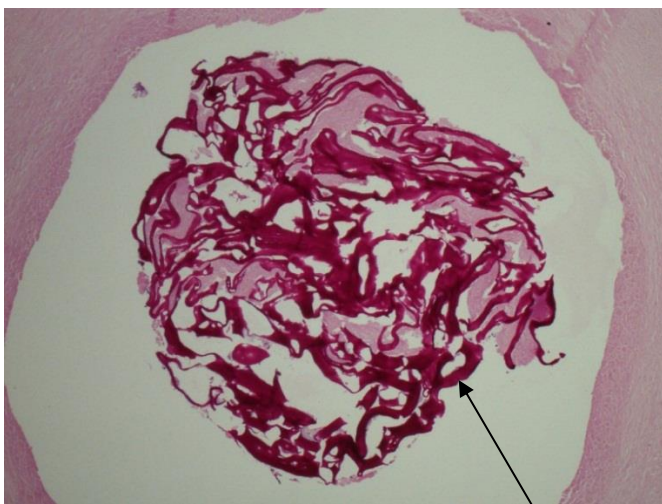


Selected Pathology Images for Alveolar Echinococcosis

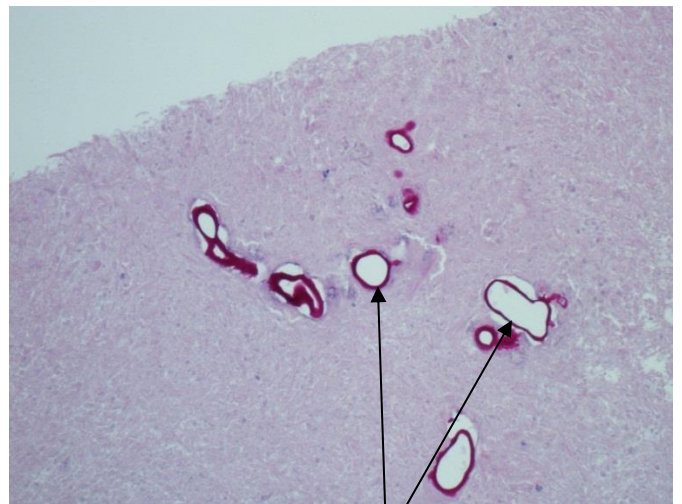


Alveolar Echinococcosis - Human Liver- Gross Examination



PAS stain

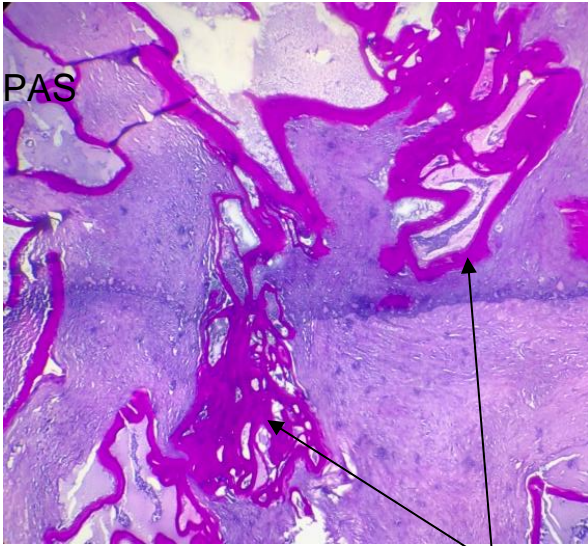
Laminated Membranes



PAS stain

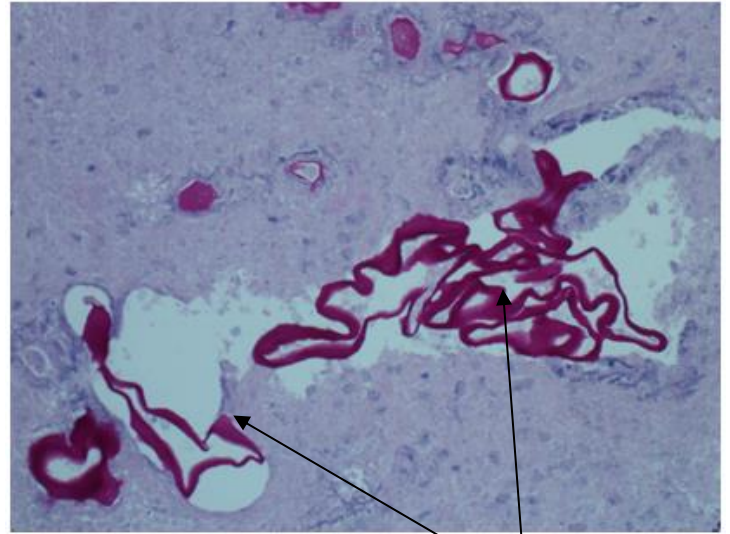
Laminated Membranes

Selected Pathology Images for Alveolar Echinococcosis



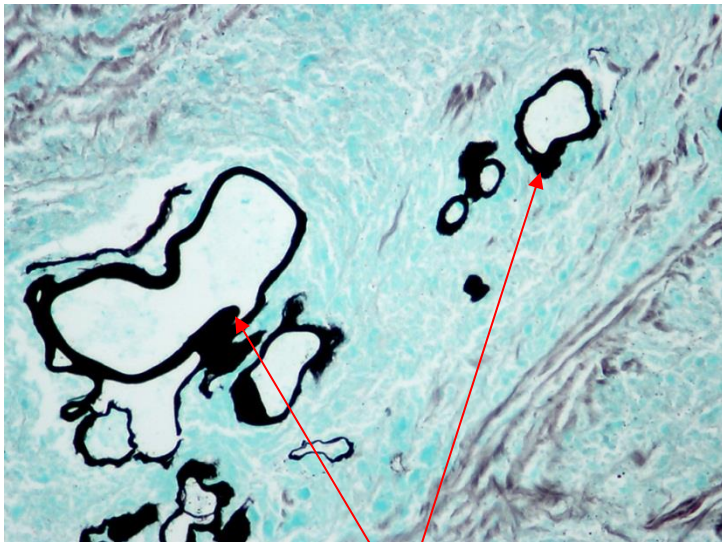
PAS stain

Laminated Membranes



PAS stain

Laminated Membranes



GMS stain

Laminated Membranes

For more information, please go to the main [Alveolar Echinococcosis \(E. multilocularis\) document](#)